



P-ISSN: 2349-8528

E-ISSN: 2321-4902

IJCS 2019; 7(4): 2090-2092

© 2019 IJCS

Received: 16-05-2019

Accepted: 18-06-2019

**Lalrinkima**

M.V. Sc. Scholar, Department of Veterinary Pathology, College of Veterinary Sciences and Animal Husbandry, Central Agricultural University, Selesih, Aizawl, Mizoram, India

**R Ravindran**

Assistant Professor (SS), Department of Veterinary Pathology, College of Veterinary Sciences and Animal Husbandry, Central Agricultural University, Selesih, Aizawl, Mizoram, India

**TK Rajkhowa**

Professor, Department of Veterinary Pathology, College of Veterinary Sciences and Animal Husbandry, Central Agricultural University, Selesih, Aizawl, Mizoram, India

**Y Damodar Singh**

Assistant Professor (SS), Department of Veterinary Pathology, College of Veterinary Sciences and Animal Husbandry, Central Agricultural University, Selesih, Aizawl, Mizoram, India

**Rahul Singh Arya**

Assistant Professor, Department of Veterinary Pathology, College of Veterinary Sciences and Animal Husbandry, Central Agricultural University, Selesih, Aizawl, Mizoram, India

**Lalchhanhima**

M.V.Sc Scholar, Department of Veterinary Gynecology & Obstetrics, College of Veterinary Sciences and Animal Husbandry, Central Agricultural University, Selesih, Aizawl, Mizoram, India

**Malsawmsangi**

M.V.Sc, Department of Veterinary Clinical Medicine, Madras Veterinary College, Chennai, Tamil Nadu, India

**Correspondence****Lalrinkima**

M.V. Sc. Scholar, Department of Veterinary Pathology, College of Veterinary Sciences and Animal Husbandry, Central Agricultural University, Selesih, Aizawl, Mizoram, India

## Study on pathology of urogenital system of dogs

**Lalrinkima, R Ravindran, TK Rajkhowa, Y Damodar Singh, Rahul Singh Arya, Lalchhanhima and Malsawmsangi**

**Abstract**

A total of 16 number of postmortem examination was conducted and examined for gross and histopathological changes in kidney during the study period. Kidney samples were collected in neutral buffer formalin and were processed for histopathological examination. Haemorrhages and congestion of the cortex and medulla were common gross pathological changes observed. One kidney was showing multiple miliary abscess on both sides of the cortex. Histopathological examination of kidney showed glomerulonephritis and tubulo interstitial nephritis.

**Keywords:** Canine, kidney, gross, histopathology, H & E

**Introduction**

Renal diseases are common in cats and dogs. The disease states of these animals are similar to those of humans. Therefore, these animals are model for investigation of kidney diseases in humans (Yhee *et al.* 2010; Mitani *et al.* 2012) <sup>[1, 2]</sup>. Historical information, physical examination and clinical laboratory data often allow for the differentiation of renal diseases into the general categories of acute renal failure, chronic renal failure and glomerular disease. Nephritis, glomerulonephritis, congestion, haemorrhage and tubular degeneration are the most common pathological lesion observed in kidney of dogs (Jubb and Kennedy, 1970) <sup>[3]</sup>. Acute interstitial nephritis is an important disease of dogs and the causal agent *Leptospira canicola* can also infect man and other animals. The clinical and histopathological features of the disease in dog are well documented (Mc Intyre and Montgomery, 1952; Monlux, 1953) <sup>[4, 5]</sup>. Different types of nephritis that are most commonly observed in dogs are chronic interstitial nephritis and glomerulonephritis (Hottendorf and Nielsen, 1968) <sup>[6]</sup>.

**Materials and methods****Sample collection**

A total of 16 number of postmortem examination were conducted during the period of study. Kidney samples were collected and preserved in 10% neutral buffer formalin for histopathological examination.

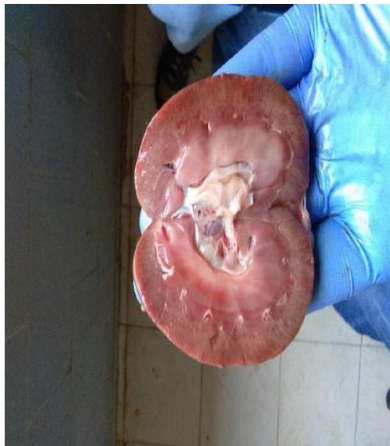**Histopathological examination of tissues**

Formalin fixed tissues (2-3 mm thick) were taken, washed overnight in running tap water and then dehydrated in ascending grades of alcohol starting from 30%, 50%, 70%, 90% and absolute alcohol I, absolute alcohol II and finally cleared in xylene. These dehydrated tissue pieces were embedded in molten paraffin. Sections were cut at 4-5  $\mu$ m thick with semi-automatic rotatory microtome (MRS 3500, Histoline Laboratories) and stained with Mayer's hematoxylin and eosin (Bancroft and Stevens, 1980). The stained slides were examined under a trinocular research microscope (Olympus) and the magnified images of the tissues structures were captured for further study.

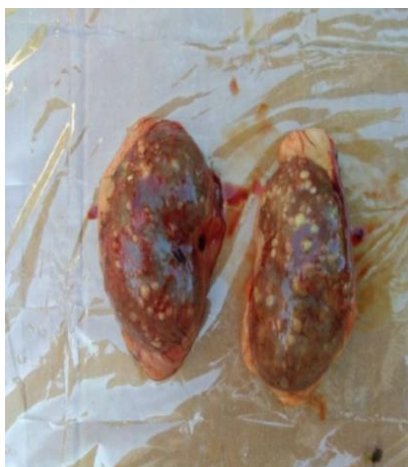**Results and discussions**

Grossly, haemorrhages and congestion on the cortex and medulla were a common findings during the study period (Fig.1). One dog kidney was showing multiple miliary abscesses formation on both sides of the cortex (Fig.2). Hess and Ilan (2003) <sup>[8]</sup> reported that renal abscess are rare in dogs. Histopathological examination of kidney showed tubulo interstitial nephritis, severe haemorrhages, congestion and infiltration of mono nuclear cells around

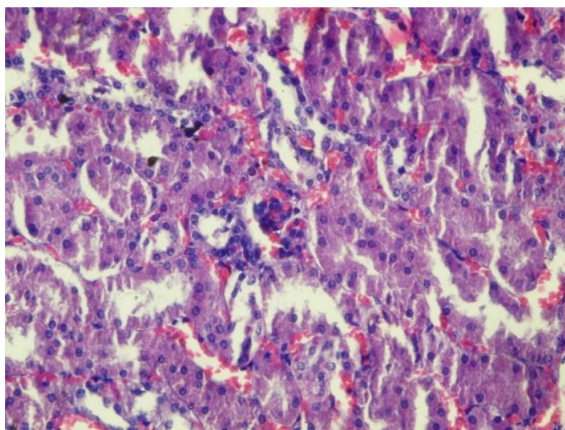
degenerating tubules (Fig.3) which was earlier reported by other worker in canine monocytic ehrlichiosis infection which could be due to this condition (Lakkawar *et al.* 2003) <sup>[9]</sup>. Glomerulonephritis indicated by severe congestion within the glomerulus along with infiltration of mononuclear cells and swollen tubular epithelium was observed (Fig.4). Ortega-Pacheco *et al.* (2008) <sup>[10]</sup> and Dash *et al.* (2018) <sup>[11]</sup> discussed these conditions which was affected with *Leptospira* infection which could be due to this condition. Abscess in kidney was indicated by necrotic areas showing severe haemorrhages and infiltration of neutrophils. Similar lesion was earlier described by Agut *et al.* (2004) <sup>[12]</sup> and Abraham *et al.* (2003) <sup>[13]</sup> in dogs associated with *E. coli* which could be due to this condition (Fig.5)



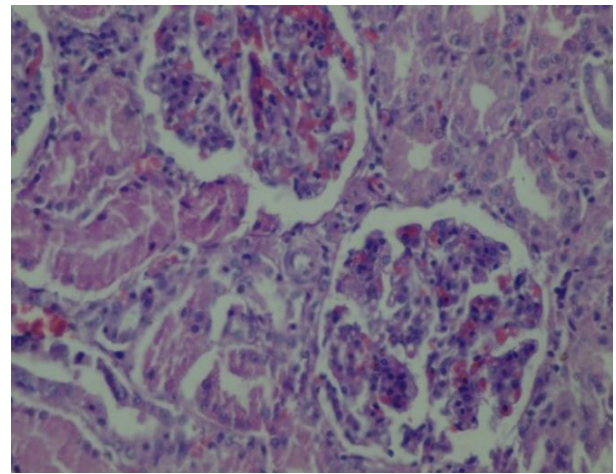
**Fig 1:** Kidney showing congestion on the cortex and medulla



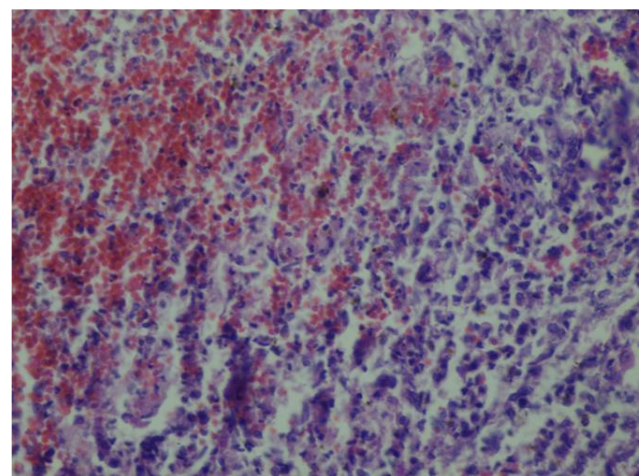
**Fig 2:** Kidney showing multiple abscess in both the lobes



**Fig 3:** Kidney showing nephritis indicated by severe congestion and presence of mononuclear cells (H & E, 400x)



**Fig 4:** Kidney showing glomerulonephritis indicated by congestion and presence of Inflammatory cells within the glomerulus (H & E, 400x)



**Fig 5:** Kidney showing necrotic areas along with severe haemorrhages and infiltration of neutrophils (H & E, 400x).

### References

1. Yhee J, Yu C, Kim J, Im K, Chon S, Sur J. Histopathological retrospective study of canine renal disease in Korea, 2003–2008. *J Vet. Sci.* 2010; 11:277-283.
2. Mitani S, Yabuki A, Taniguchi K, Yamato O. Association between the intrarenal renin-angiotensin system and renal injury in chronic kidney disease of dogs and cats. *J Vet. Med. Sci.* 2012; 75:127-133.
3. Jubb KVF, Kennedy PC. *Pathology of Domestic Animals.* Academic Press, New York and London, 1970, 203.
4. Mc Intyre WIM, Montgomery GL. Renal lesions in *Leptospira canicola* infection in dogs. *J Pathol. Bacteriol.* 1952; 64:145.
5. Monlux AW. The histopathology of nephritis of the dog. I. Introduction. 11. Inflammatory interstitial diseases. *Am. J. Vet. Res.* 1953; 14:425.
6. Hottendorf GH, Nielsen SW. Pathologic report of twenty—nine necropsies on dogs with mastocytoma. *Vet. Pathol.* 1968; 5(2):102-121.
7. Bancroft JD, Stevens A. *Theory and practice of histologic technique.* Churchill Livingstone, New York, 1980, 89.
8. Hess RS, Ilan I. Renal abscess in a dog with transient diabetes mellitus. *J Small Anim. Pract.* 2003; 44:13-16.

9. Lakkawar AW, Nair MG, Varshney KC, Sreekrishnan R, Rao VN. Pathology of canine monocytic ehrlichiosis in a German Shepherd dog. *Slov. Vet. Res.* 2003; 40:123-132.
10. Ortega-Pacheco A, Colin-Flores RF, Gutiérrez-Blanco E, Jiménez-Coello M. Frequency and type of renal lesions in dogs naturally infected with *Leptospira* species. *Ann. N. Y. Acad. Sci.* 2008; 1149(1):270-274.
11. Dash BR, Dhaygude VS, Gadhave PD, Garud KV, Kadam DP. Molecular detection of *Leptospira* spp. from canine kidney tissues and its association with renal lesions. *Vet. World.* 2018; 11(4):530.
12. Agut A, Laredo FG, Belda E, Seva J, Soler M. Left perinephric abscess associated with nephrolithiasis and bladder calculi in a bitch. *Vet. Rec.* 2004; 154(18):562-565.
13. Abraham LA, Beck C, Slocombe RF. Renal dysplasia and urinary tract infection in a Bull Mastiff puppy. *Aust. Vet. J.* 2003; 81(6):336-339.